

WRITTEN EXAMINATION SHORT ANSWER QUESTIONS (SAQ)

NSW Fellowship Course Trial Exam 2018:1

EXAMINATION TIME: 3 HOURS

DIRECTIONS TO CANDIDATE

1. Answer each question in the space provided in this question paper.
2. Enter your examination number in the spaces provided
3. Write your candidate number on every page — the booklet will be separated for marking purposes.
4. DO NOT write your name on the examination booklet.

AFTER THE EXAMINATION

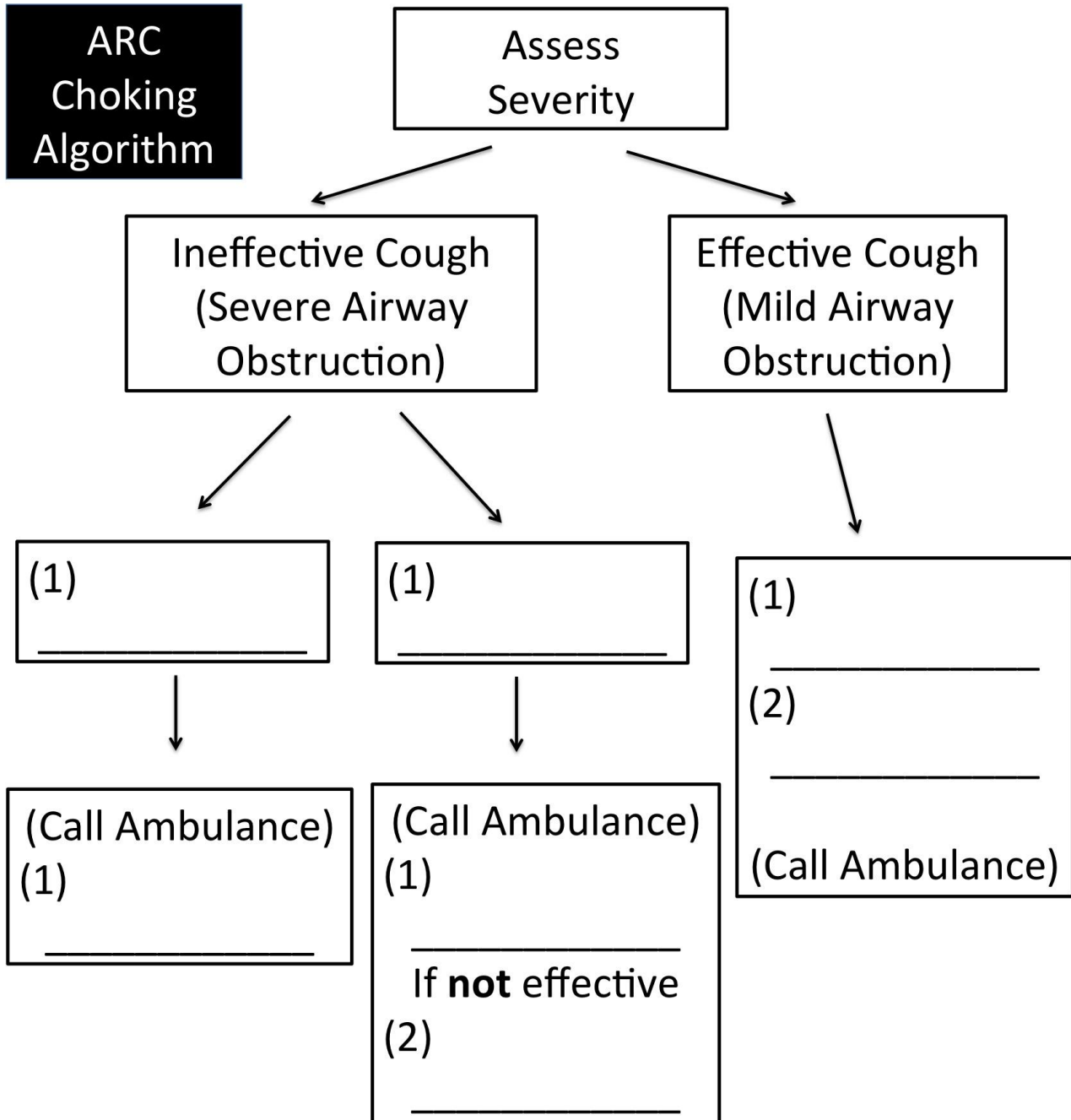
- Prior to leaving today, please fill out an envelope with your return address
- Feedback session - held at Westmead Hospital (Level 1 Cabaret Room) on 1/2/18 (9am)

Page intentionally left blank

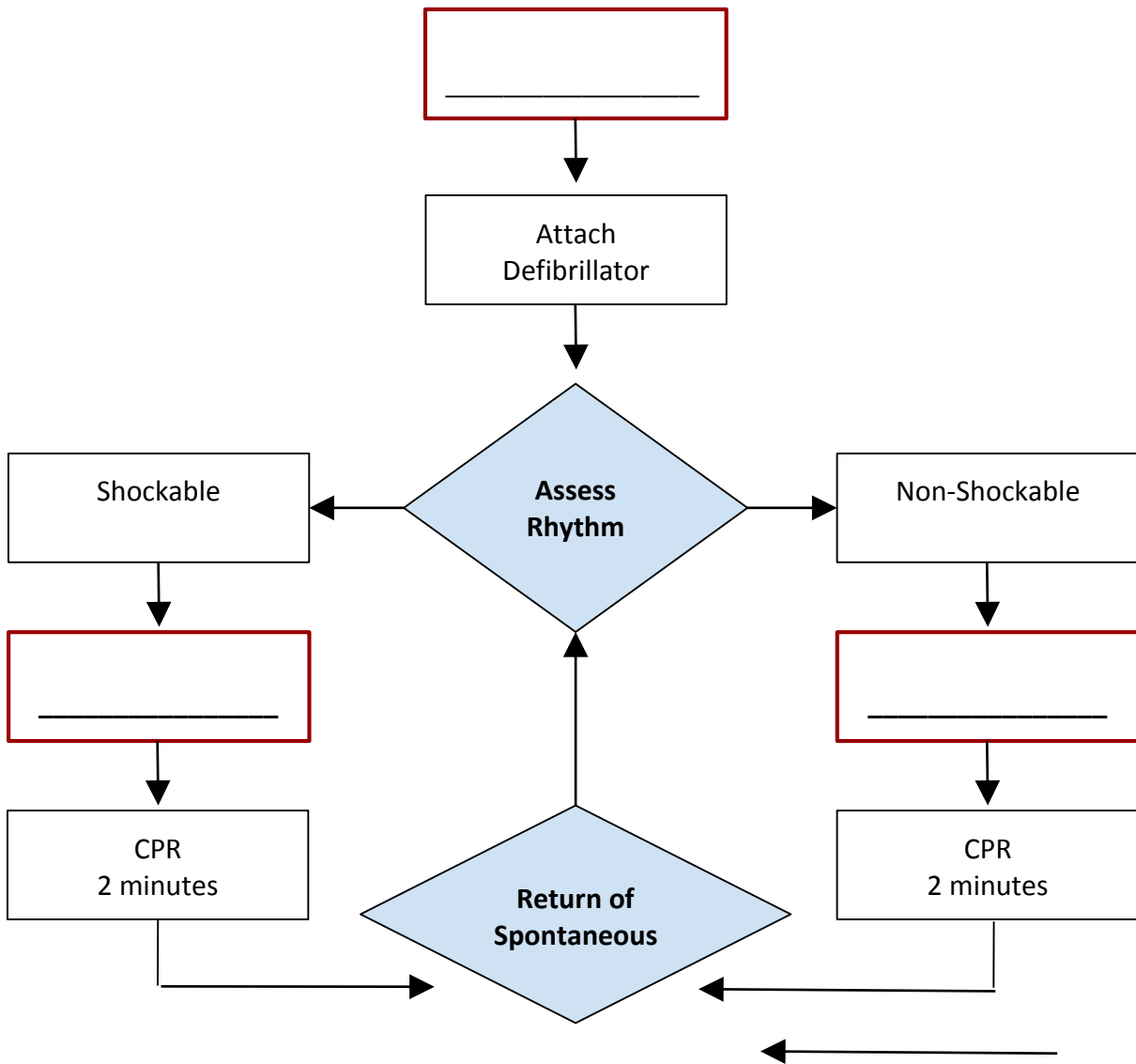
Question 1 (10 marks)

You attend an 11-month old boy choking in a restaurant. An ambulance has been called.

(i) Fill in the spaces in the numbered boxes for the PRE-HOSPITAL approach to a choking child from the Australian Resuscitation Council (ARC) algorithm. (7 marks)



(ii) In the figure below, fill in the three (3) blank boxes to complete the PAEDIATRIC Australian Resuscitation Council (ARC) cardiac arrest algorithm. The child's weight is 10kg. (3 marks)



Question 2 (13 marks)

A 15 year old boy presents with shortness of breath for 24 hours. His chest x-ray is provided. His vitals are within the normal range.

(i) State the significant finding on the chest x-ray provided (1 mark)

	X-ray Finding
(1)	

(ii) List three (3) possible causes for the chest x-ray abnormality (3 marks)

	Causes for the chest x-ray abnormality
(1)	
(2)	
(3)	

(iii) State three (3) specific management options and one (1) advantage and one (1) disadvantage for each option (9 marks)

Specific Management	Advantage	Disadvantage
(1)		
(2)		
(3)		

Page intentionally left blank

Question 3 (23 marks)

A 4 year old girl is brought to the ED after a fall. She has complained of left elbow pain since the accident. She weighs 16kg.

(i) State two (2) important findings on the two (2) elbow x-rays provided (2 marks)

i)

ii)

(ii) List the typical order of ossification on a paediatric elbow x-ray (6 marks)

Ossification Centre	Answer(s)
1st	
2nd	
3rd	
4th	
5th	
6th	

(iii) List two (2) nerves that may sustain a neuropraxia as a complication of this injury (2 marks)

i)

ii)

(iv) List three (3) pharmacological agents, other than ketamine, that you would consider for initial analgesia in this child. Include dose and route of administration. (3 marks)

Pharmacological Agent	Dosing and Route

(v) To facilitate the placement of a long arm back slab sedation is required. Complete the following table regarding the use of ketamine in paediatric procedural sedation (10 marks)

	Intramuscular (IM)	Intravenous (IV)
Initial dose		
Peak effect		
Duration of action		
Two (2) advantages of the stated route of administration	(1) _____ (2) _____	(1) _____ (2) _____

Question 4 (10 marks)

A 72 year old man is brought to ED following an intentional ingestion of sodium nitrite tablets used for cleaning his dentures. He has no past medical history. On examination his airway is patent and his respiratory examination is normal.

The O₂ saturations are recorded at 85% regardless of the level of oxygen titration.

(i) List three (3) bedside investigations you would perform immediately for this patient (3 marks)

i)

ii)

iii)

(ii) State a single unifying diagnosis for this patient's presentation and one underlying condition associated with developing the condition and an increased risk of failing to respond to treatment (2 marks)

Unifying Diagnosis	
Underlying Condition	

(iii) State the treatment of choice for this presentation. (1 mark)

Treatment of Choice	
---------------------	--

(iv) State one (1) additional therapy used to treat this condition (1 mark)

(v) List three (3) toxic ingestions/exposures that can cause this condition (3 marks)

i)

ii)

iii)

Question 5 (23 marks)

A 42 year old non-english speaking woman presents with an acute exacerbation of asthma. This is the third presentation with asthma in the last month.

(i) State four (4) features on history that would suggest poor asthma control (4 marks)

i)

ii)

iii)

iv)

(ii) If the patient was medically appropriate for discharge, list five (5) key steps you would take in order to safely discharge her from hospital (5 marks)

i)

ii)

iii)

iv)

v)

Your assessment suggests she has life-threatening asthma. You trial non invasive ventilation (NIV) therapy.

(iii) List two (2) advantages and two (2) disadvantages of NIV in severe asthma (4 marks)

Advantages	Disadvantages

(iv) Despite a trial of NIV therapy she deteriorates and is intubated for progressive respiratory failure. List and justify an action plan for the ventilator settings post intubation (6 marks)

	Setting	Justification
Tidal Volume		
I:E ratio		
Respiratory Rate		

(v) Following intubation she becomes suddenly hypotensive. State the four (4) MOST likely causes of hypotension in this patient (4 marks)

i)

ii)

iii)

iv)

Question 6 (14 marks)

A recently returned traveller is concerned about M.E.R.S. CoV (Middle East respiratory syndrome coronavirus).

(i) List three (3) aspects of the history which would make MERS CoV MOST likely (3 marks)

i)

ii)

iii)

Five (5) travelling companions of the concerned patient present to triage. You are concerned about the possibility of these patients also having MERS CoV.

(ii) List four (4) steps you would take to prepare the ED (4 marks)

i)

ii)

iii)

iv)

(iii) List four (4) personal protective precautions to take when treating these patients (4 marks)

i)

ii)

iii)

iv)

While waiting in isolation, one of the patients becomes agitated and demands to leave.

(iv) State three (3) management principles underlying an approach to this patient (3 marks)

i)

ii)

iii)

Question 7 (13 marks)

You have been tasked with updating the Emergency Department sepsis pathway.

(i) List three (3) components of the Q-SOFA score (3 marks)

i)

ii)

iii)

(ii) Other than 'Q-SOFA scoring' list four (4) key changes to the international sepsis guidelines occurring in 2017 (4 marks)

i)

ii)

iii)

iv)

(iii) State three (3) findings in the history and three (3) investigation results that are associated with an increased mortality in a patient with septic shock (6 marks)

	History Features	Investigation Results
Finding 1		
Finding 2		
Finding 3		

Question 8 (14 marks)

A 20 year old man presents with an isolated injury after a fall onto his outstretched arm.

(i) List two (2) significant findings on the photograph of the patient's wrist provided (2 marks)

i)

ii)

(ii) List six (6) priorities in the management of this patient's injury (6 marks)

i)

ii)

iii)

iv)

v)

vi)

(iii) List 2 (two) immediate and two (2) late complications of this injury (4 marks)

Immediate Complications	Late Complications
(1)	(1)
(2)	(2)

(iv) List two (2) examination findings suggestive of a traumatic median nerve injury (2 marks)

i)

ii)

Question 9 (12 marks)

A patient presents to the ED with vomiting and chest pain. He was discharged from the ED short stay unit 48 hours ago with a diagnosis of 'cannabis hyperemesis syndrome'.

You are asked to review his chest x-ray (CXR) which is reported as '*pneumomediastinum, otherwise normal*'. He re-presents at your request.

(i) List the MOST likely causes of pneumomediastinum in this patient (3 marks)

	Causes of pneumomediastinum
MOST likely cause	
Other cause 1	
Other cause 2	

(ii) On arrival at triage he is febrile, tachycardic and hypotensive. List four (4) initial management priorities in this case (4 marks)

i)

ii)

iii)

iv)

After a preliminary investigation you discover several incidences of missed CXR findings.

(iii) List five (5) measures that could be implemented in your department to reduce the risk of missed CXR findings (5 marks)

i)

ii)

iii)

iv)

v)

Question 10 (14 marks)

A 36 year old female presents to your ED with diplopia of gradual onset. She also reports lethargy and weakness. She has been previously well other than hypothyroidism for which she is prescribed 100 micrograms of thyroxine daily.

(i) List four (4) neurological diagnoses to account for the presentation. For each condition listed state one (1) clinical examination finding (aside from diplopia) and one (1) investigation finding which would support each diagnosis (12 marks)

Diagnosis	Clinical Examination Finding	Investigation Finding
(1)		
(2)		
(3)		
(4)		

(ii) List two (2) important bedside measures of respiratory function that could be used in the assessment of this patient (2 marks)

i)

ii)

Page intentionally left blank

Question 11 (22 marks)

A 23 year old male presents to a rural ED. His family are concerned that he has taken an overdose and is at risk of self harm. His blood sugar is in the normal range.

A point of care venous blood gas (VBG) sample is taken:

		(Reference ranges)
● pH	7.34	(7.35 - 7.45)
● Bicarbonate	16 mmol/L	(22 - 28)
● Base excess	-6	(-2 to 2)
● pO ₂	105 mmHg	(80 - 110)
● pCO ₂	31 mmHg	(36 - 45)
● lactate	9.6 mmol/L	(< 2)
● Na	136 mmol/L	(135 - 145)
● Cl	104 mmol/L	(95 - 110)
● K	4.2 mmol/L	(3.2 - 5.0)

(i) State two (2) primary acid-base abnormalities on this blood gas (2 marks)

i)

ii)

(ii) State the calculation you would make for the 'expected' CO₂ (1 mark)

i)

(iii) State the three (3) MOST likely causes of the abnormal results (3 marks)

i)

ii)

iii)

There is clinical concern about ethylene glycol ingestion.

(iv) List two (2) features on blood gases that are MOST specific when assessing for this toxic alcohol ingestion? (2 marks)

i)

ii)

(v) List and justify four (4) investigations that are important in the assessment of a patient with ethylene glycol ingestion. (8 marks)

Investigation	Justification
(1)	(1)
(2)	(2)
(3)	(3)
(4)	(4)

It emerges that this patient has ingested a significant volume ethylene glycol.

(vi) List and justify three (3) immediate emergency department management priorities. For any medications/fluids include dose and route. (6 marks)

Management	Justification

Page intentionally left blank

Question 12 (15 marks)

A 3 year old female is brought in by ambulance following a first presentation of a 'generalised tonic clonic seizure'. Paramedics state that the event lasted 10 minutes and terminated with administration of buccal midazolam. She was incontinent of urine.

(i) List four (4) causes of a 'generalised tonic clonic seizure' in this patient (4 marks)

i)

ii)

iii)

iv)

(ii) List and justify two (2) bedside, two (2) laboratory and one (1) imaging investigation you would perform in this case (10 marks)

	Investigation Selected	Justification
Bedside Tests (2)	(1) _____	(1) _____
	(2) _____	(2) _____
Imaging Tests (1)	(1) _____	(1) _____
Laboratory Tests (2)	(1) _____	(1) _____
	(2) _____	(2) _____

(iii) State the three (3) MOST important priorities if the child has a further seizure (3 marks)

i)

ii)

iii)

Question 13 (16 marks)

You are notified that a 24 year old female has presented to your urban ED in precipitous labour. She has not received any antenatal care. The gestational age is unknown.

(i) List three (3) important immediate actions you would take (3 marks)

i)

ii)

iii)

Your assessment is that she is rapidly progressing towards delivery in the ED.

(ii) List three (3) factors that predispose to a breech delivery (3 marks)

i)

ii)

iii)

The newborn is successfully delivered but is flaccid and apnoeic (APGAR of 0)

(iii) List two (2) immediate treatment priorities (2 marks)

i)

ii)

(iv) List two (2) pieces of essential equipment from each of the four (4) categories outlined below that you would require to manage this precipitous delivery (8 marks)

Equipment Category	Choice of Equipment
Manage the delivery	<ul style="list-style-type: none">• _____• _____
Neonatal resuscitation - General	<ul style="list-style-type: none">• _____• _____
Neonatal resuscitation - Airway	<ul style="list-style-type: none">• _____• _____
Drugs and/or Fluids (with doses)	<ul style="list-style-type: none">• _____• _____

Question 14 (13 marks)

A 4 year old male has presented to the ED with a suspected nasal foreign body. His mother reports that he was playing with a beaded necklace when it broke and beads were found scattered on the floor.

(i) If a foreign body is NOT seen under direct vision, list two (2) clinical features that suggest the presence of an occult nasal foreign body (2 mark)

i)

ii)

On examination a green spherical foreign body is visualised. The family have consented for the nasal foreign body removed under conscious sedation.

(ii) List three (3) pieces of equipment you would prepare for this procedure, which would assist you in removing the foreign body (3 marks)

i)

ii)

iii)

(iii) State two (2) indications to refer this case to a ENT surgeon (2 marks)

i)

ii)

(iv) State two (2) techniques for removal, and highlight one (1) advantage and one (1) disadvantage for each technique. (6 marks)

Technique	Advantage	Disadvantage

Question 15 (12 marks)

A 24-year-old female has presented to your ED with fever and a rash with an appearance of 'rose spots'. She is an overseas student and she returned 2 weeks ago from an extended holiday in Bangladesh. She was referred to ED by her GP because her blood cultures demonstrated 'Salmonella species' (identification and sensitivities to follow).

There is no past medical history, allergies or regular medications. She is not pregnant.

(i) List four (4) features on the history (specific to salmonella typhi spp infection) that you would ask about (4 marks)

i)

ii)

iii)

iv)

Her bloods show a moderate microcytic anaemia and mild thrombocytopenia.

(ii) State two (2) further tests MOST useful for diagnosing the cause of fever (2 marks)

i)

ii)

On examination, she is febrile and tachycardic. You decide that she requires admission.

(iii) Prescribe two (2) antibiotics that you will commence (2 marks)

Drug	Dose/Frequency	Route

The blood culture has now flagged positive for 'Salmonella Typhi'.

(iv) State how this infection is transmitted and what precautions are required to prevent its spread (2 marks)

Route of Transmission	
Precautions	

(v) State two (2) complications that can occur following acute Salmonella infection (2 marks)

i)

ii)

Question 16 (12 marks)

You have received a call from the ambulance control that an explosion has occurred near your urban ED. You expect that a number of blast victims will present to ED.

(i) In the following table state how the four (4) types of blast injury are caused (4 marks)

	Description
Primary	
Secondary	
Tertiary	
Quaternary	

(ii) List four (4) important actions you would take prior to arrival of the victims (4 marks)

i)

ii)

iii)

iv)

(iii) List the MOST likely injuries expected for each category of blast injury (4 marks)

	Most Likely Injuries
Primary	
Secondary	
Tertiary	
Quaternary	

Page intentionally left blank

Question 17 (15 marks)

You have been tasked with providing an update to the other ED staff on the use of point of care ultrasound (POCUS).

You have been asked to prepare a brief tutorial in the use of ultrasound in cardiac arrest.

(i) List three (3) recognised general uses of POCUS in the assessment of an adult patient in cardiac arrest (3 marks)

i)

ii)

iii)

(ii) In the following table list eight (8) reversible causes of cardiac arrest (8 marks)

(1)	(2)	(3)	(4)
(5)	(6)	(7)	(8)

(iii) For two (2) of the causes listed in Question (ii), list two (2) actual sonographic findings you would look for on your POCUS (4 marks)

Cause of Cardiac Arrest	SPECIFIC Sonographic Finding on POCUS exam

Page intentionally left blank

Question 18 (13 marks)

You arrive on the scene of this train derailment illustrated in the 2 photos provided.

(i) List three (3) immediate actions you would perform at the scene (3 marks)

i)

ii)

iii)

(ii) List three (3) potential hazards shown in the photo (3 marks)

i)

ii)

iii)

(iii) State seven (7) specific pieces of information you would give over the phone to the emergency services about this disaster as the first responder (7 marks)

i)

ii)

iii)

iv)

v)

vi)

vii)

Question 19 (12 marks)

A 4 year old girl presents to your ED after being found next to an empty vaporiser bottle containing 100% eucalyptus oil. On arrival she has the following vital signs:

- Heart rate 120 / min
- BP 98 / 60 mmHg
- RR 26 / min
- Sat 94% (Room Air)
- Temp 36.1°C

(i) List three (3) sequelae of poisoning from 100% eucalyptus oil (3 marks)

i)

ii)

iii)

(ii) State four (4) key priorities in the acute management of this patient (4 marks)

i)

ii)

iii)

iv)

v)

(iii) List the five (5) components of a general toxicology 'risk assessment' (5 marks)

i)

ii)

iii)

Question 20 (12 marks)

The director of your ED is planning to purchase a mechanical chest compression machine and a waveform capnography device. You are tasked with leading the procurement process.

(i) List three (3) advantages and three (3) disadvantages of mechanical CPR devices (6 Marks)

Advantages	Disadvantages
(1)	(1)
(2)	(2)
(3)	(3)

(ii) State two (2) recommendations regarding the use of mechanical CPR from the Australia and New Zealand Committee on Resuscitation (ANZCOR) (2 marks)

i)

ii)

(iii) List four (4) uses of waveform capnography in the resuscitation of a cardiac arrest patient (4 marks)

i)

ii)

iii)

iv)

Question 21 (13 marks)

A 6-month old infant is brought to an urban ED by his mother. He has a swollen and bruised left thigh. You are concerned about '*non-accidental injury*'.

(i) List five (5) specific features of the history that are MOST likely to be consistent with non-accidental injury (5 marks)

i)

ii)

iii)

iv)

v)

(ii) Excluding fractures, list three (3) OTHER injuries MOST likely to be associated with non-accidental injury (3 marks)

i)

ii)

iii)

The x-ray confirms a femur fracture. His mother requests discharge.

(iii) State five (5) priorities in the ED management of this case (5 marks)

i)

ii)

iii)

iv)

v)

Question 22 (12 marks)

A 26 year old man presents following a high speed motorbike accident.

(i) State two (2) significant POSITIVE findings on the chest x-ray provided (2 marks)

i)

ii)

The primary survey reveals:

- Airway
 - Protected and Patent
- Breathing
 - Respiratory rate 26, O2 saturations 99% (on 6L O2)
 - No obvious chest injury, severe bilateral chest wall tenderness
- Circulation
 - HR 60/min
 - BP 80/40 mmHg
 - Abdominal tenderness, no guarding
 - E-FAST ultrasound - negative
 - Right femur fracture (splinted by ambulance staff).
 - No external bleeding
- Disability
 - GCS 15
 - No scalp laceration
 - No neurological deficit

(ii) State the three (3) most likely causes of his hypotension (3 marks)

i)

ii)

iii)

(iii) State two (2) definitions of a '*massive transfusion*' (2 marks)

i)

ii)

(iv) State five (5) potential complications of a massive transfusion (5 marks)

i)

ii)

iii)

Question 23 (10 marks)

You are working a busy evening shift in a rural ED. A final year medical student interrupts you during a clinical history of a patient with chest pain. She discloses that she is concerned about her recent ED term experience being very negative.

She alleges that a junior medical officer refused to answer her clinical questions and has since 'shouted at her' on several occasions in front of patients.

(i) State three (3) immediate actions (3 marks)

i)

ii)

iii)

(ii) Other than the student concerned and the doctor performing the alleged behaviours, list three (3) other stakeholders in this situation (3 marks)

i)

ii)

iii)

You agree to take leadership on the ongoing management of the situation.

(iii) List four (4) further actions you will take to definitively manage this matter (4 marks)

i)

ii)

iii)

iv)

Question 24 (12 marks)

A 34 year old woman is brought to ED by ambulance from a shopping centre with an episode of sudden collapse (true syncope) and abdominal pain.

On examination the vital signs are in the normal range and there is no evidence of injury.

(i) State four (4) features in the history that would favour a diagnosis of '*syncope*' over '*seizure*' (4 marks)

(i)	(ii)
(iii)	(iv)

(ii) List the four (4) MOST likely diagnoses you would consider in this case and one (1) examination finding that would support each diagnosis listed (8 marks)

	Diagnosis	Supporting CLINICAL EXAMINATION Finding
(1)		
(2)		
(3)		
(4)		

Page intentionally left blank

Question 25 (13 marks)

A 3 year old child is brought to ED with a history of fever. You are concerned about measles in view of a history of incomplete vaccination. An image of the child's rash is provided.

(i) Other than measles, list three (3) differentials for the rash shown in the image (3 marks)

i)

ii)

iii)

(ii) List three (3) specific features in the history and on clinical examination that support a diagnosis of measles (6 marks)

Features on History	Features on Examination
(1)	(1)
(2)	(2)
(3)	(3)

The child is found to be otherwise well and is to be discharged home.

(iv) List three (3) further actions you would take in terms of the wider on-going management of this situation (3 marks)

i)

ii)

iii)

Question 26 (14 marks)

A 49 year old man presents to ED 1 week after abdominal surgery. The GP letter reports he had a '*laparotomy for a perforated viscus*' at an interstate hospital.

On examination he is febrile and has the appearances of an abdominal wound shown in the clinical photograph provided

(i) State your interpretation of the appearances of the photograph provided (1 mark)

i)

(ii) List three (3) patient and three (3) surgical factors that could contribute to this complication (6 marks)

Patient Factors	Surgical Factors

(iii) List two (2) further laboratory based investigations to perform in this case (2 marks)

i)

ii)

(iv) State one (1) general wound closure technique commonly used in ED and state two (2) advantages and disadvantages of the method (5 marks)

Method of Wound Closure	Advantage(s)	Disadvantage(s)
	(1)	(1)
	(2)	(2)

Question 27 (13 marks)

A 29 year old man was rescued from cold water unresponsive in pulseless electrical activity (PEA). Return of Spontaneous Circulation (ROSC) was obtained after 4 minutes of CPR and 1mg Adrenaline (IV).

The patient's post ROSC ECG on arrival is provided.

(i) List three (3) abnormalities on the ECG (3 marks)

i)

ii)

iii)

The patient's measured core temperature (rectal) is 28 degrees celsius.

(ii) List three (3) specific methods of rewarming that can be used in the ED (3 marks)

i)

ii)

iii)

(iii) List three specific (3) modifications you would make to your standard Advanced Life Support (ALS) algorithm should this patient have another cardiac arrest (3 marks)

i)

ii)

iii)

(iv) Define the four (4) stages of hypothermia (e.g. Swiss Staging System) (4 marks)

Stage 1	
Stage 2	
Stage 3	
Stage 4	

END OF EXAM PAPER

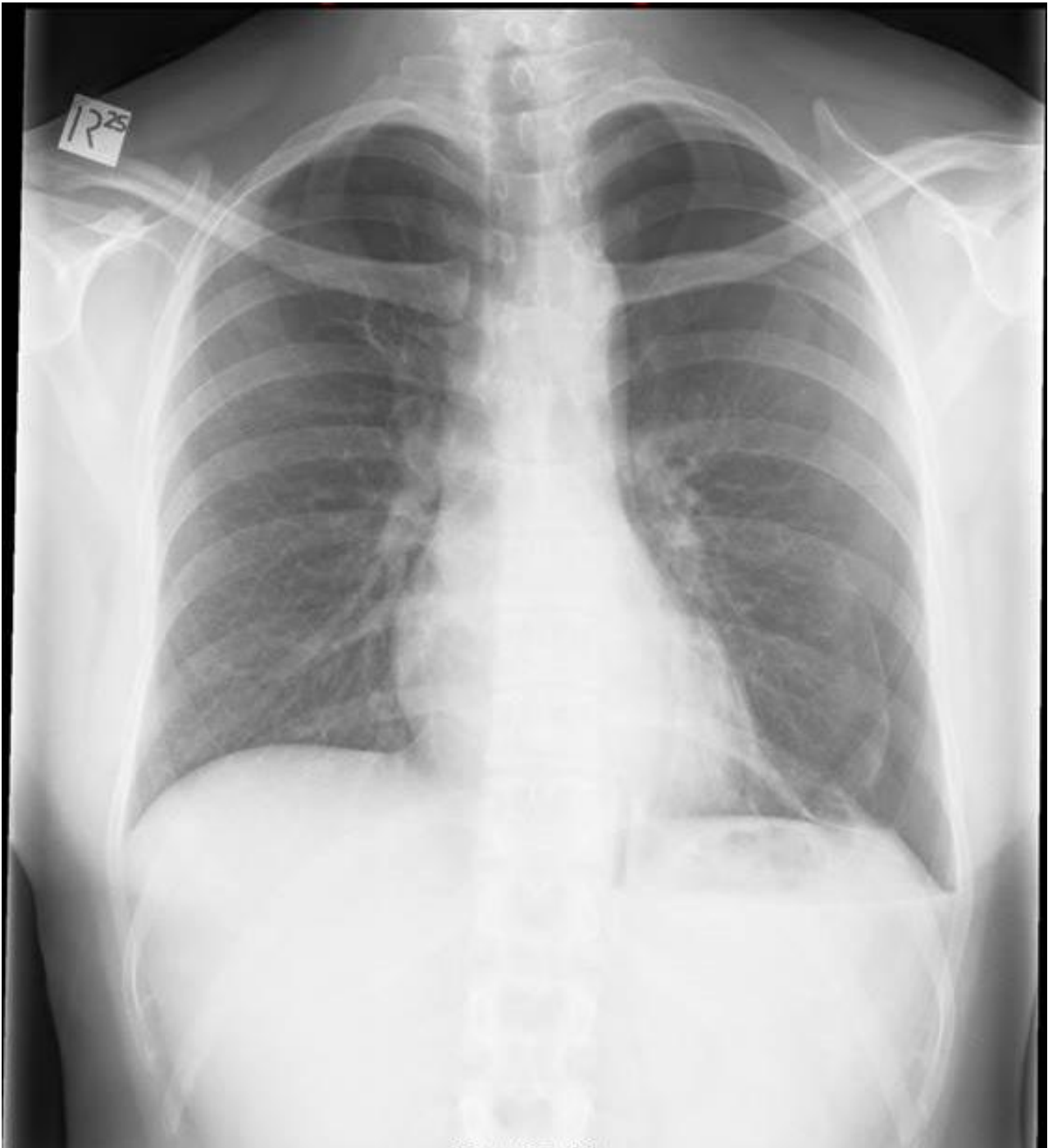Page intentionally left blank

Page intentionally left blank

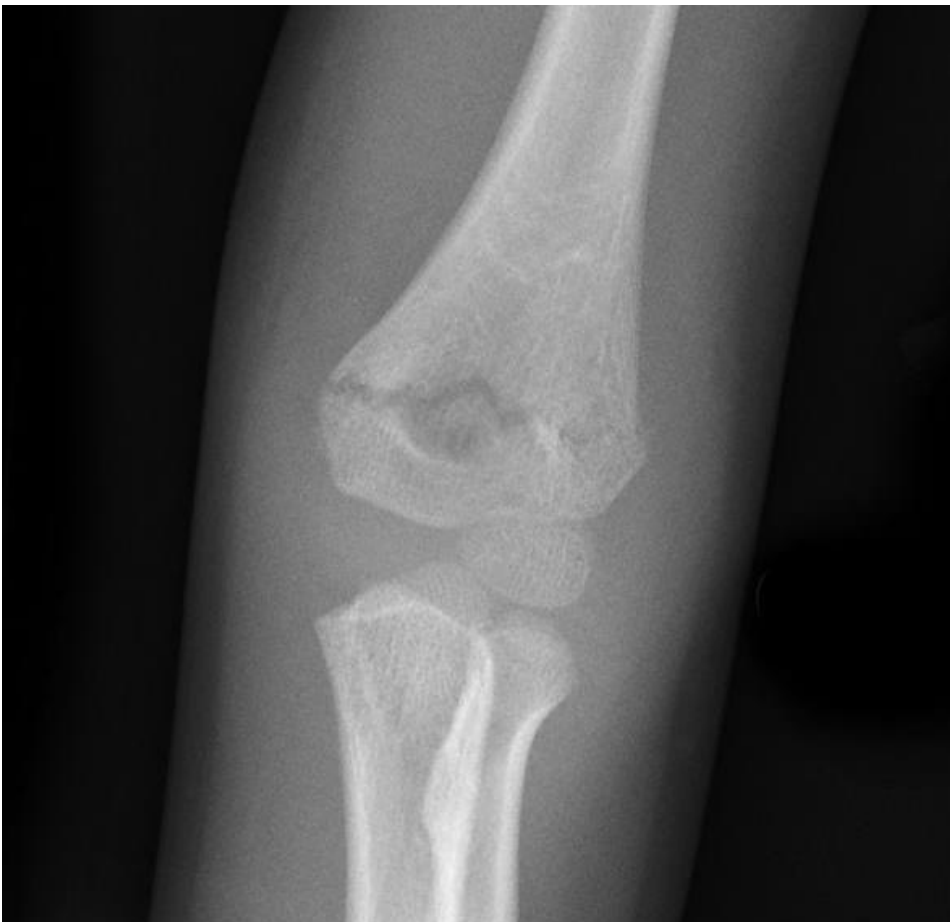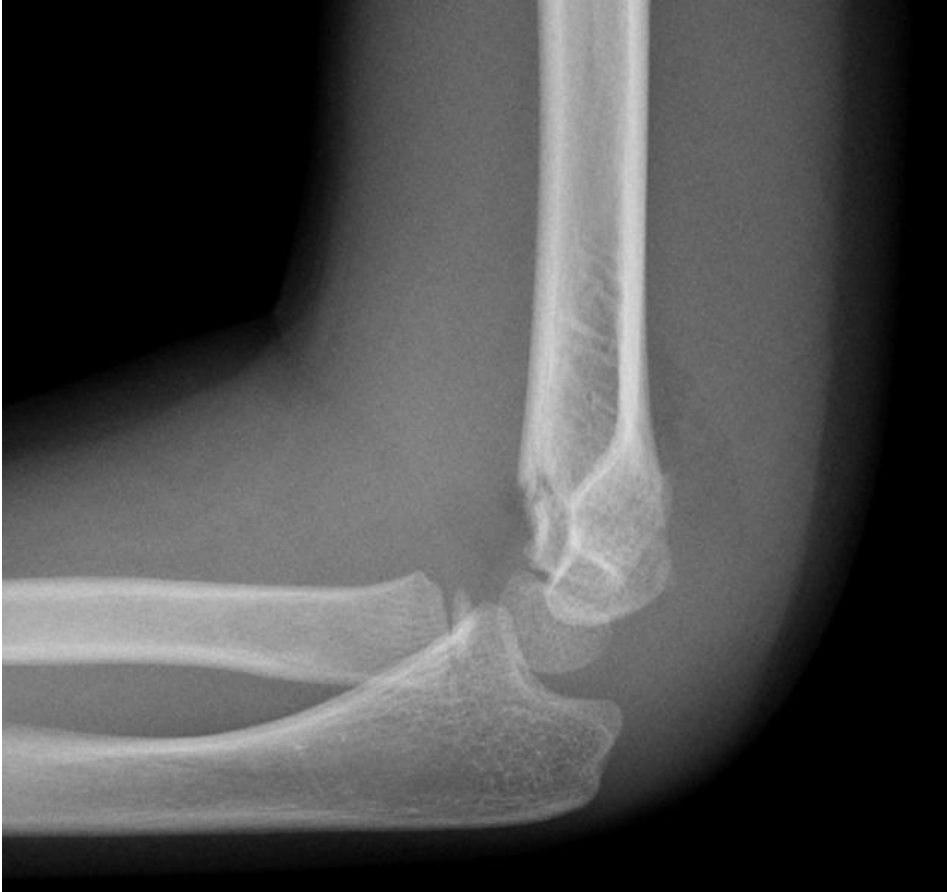WRITTEN EXAMINATION SHORT ANSWER QUESTIONS

PROP BOOKLET

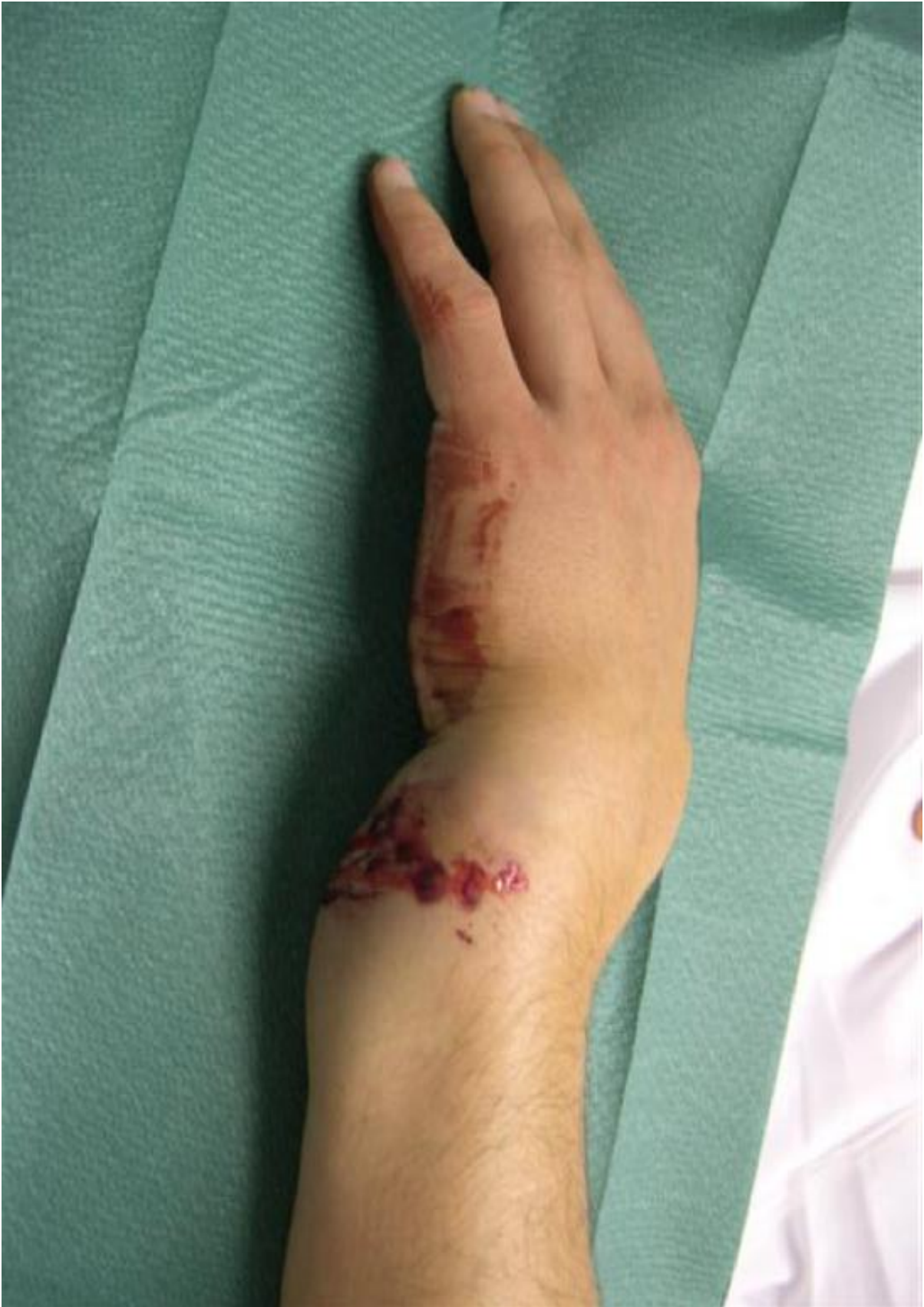Question 2 - PROP (Chest x-ray)



Question 3 - PROP (Elbow x-rays)



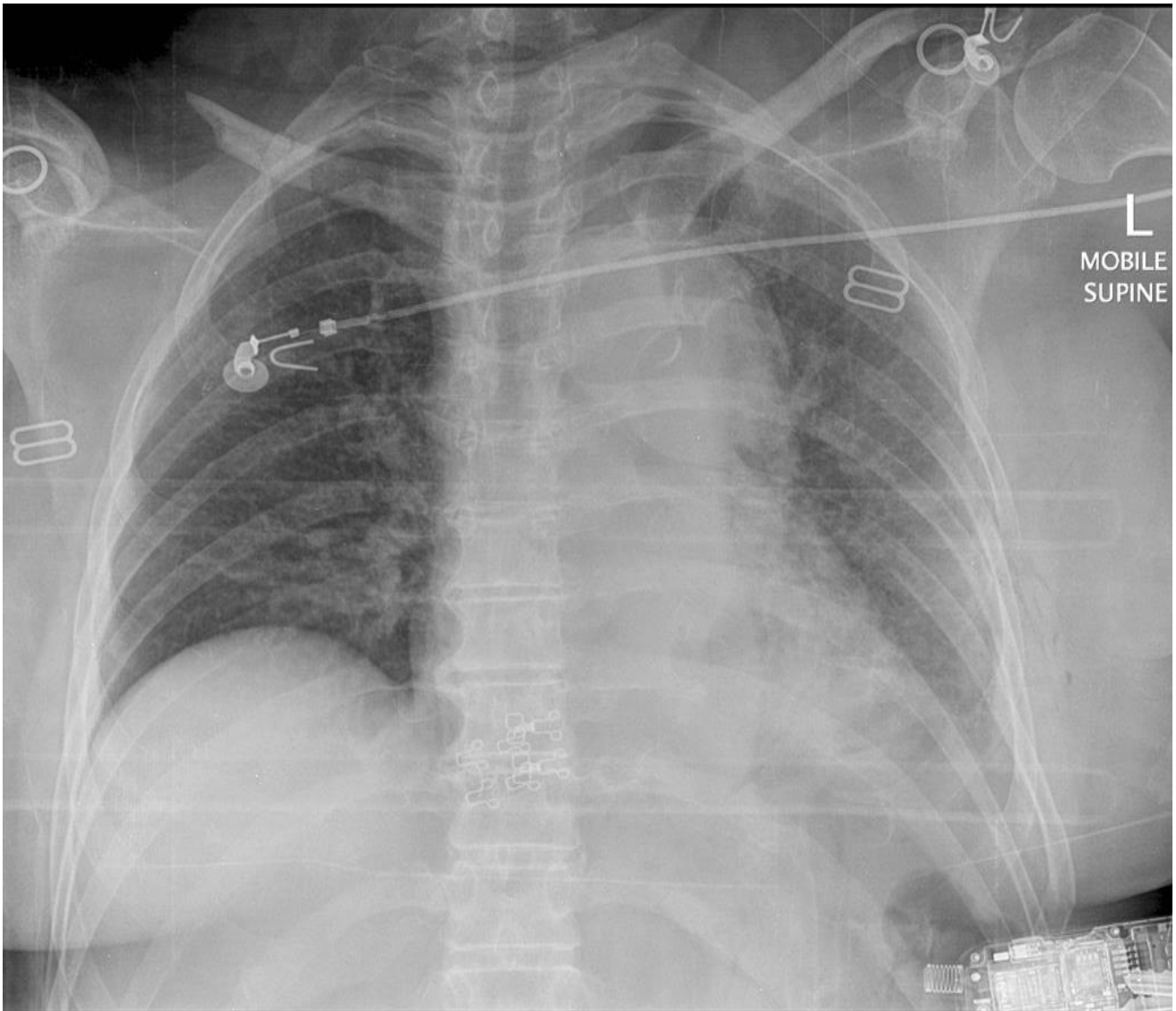
Question 8 - PROP (Clinical Photograph)



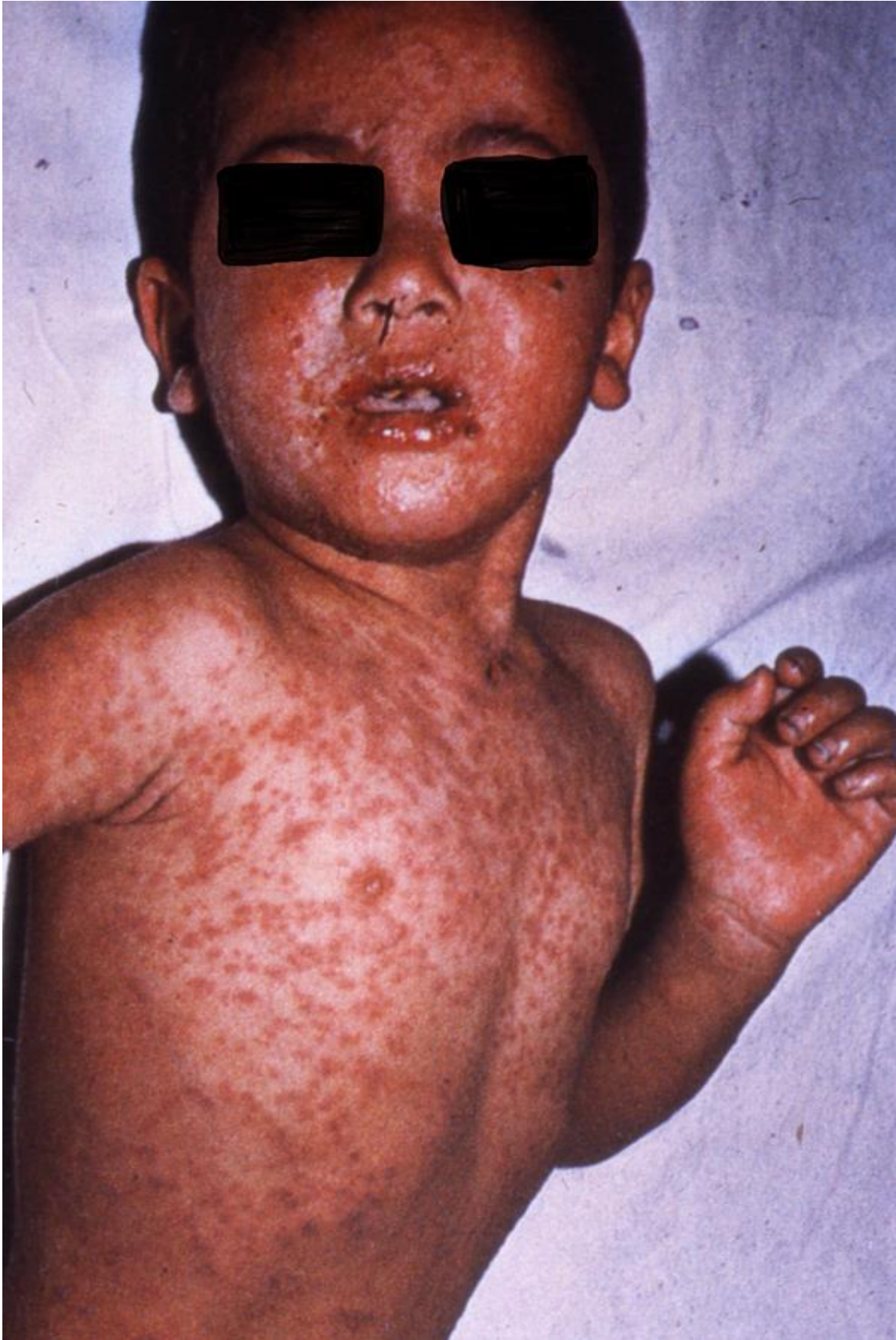Question 18 - PROP (Scene Photograph)



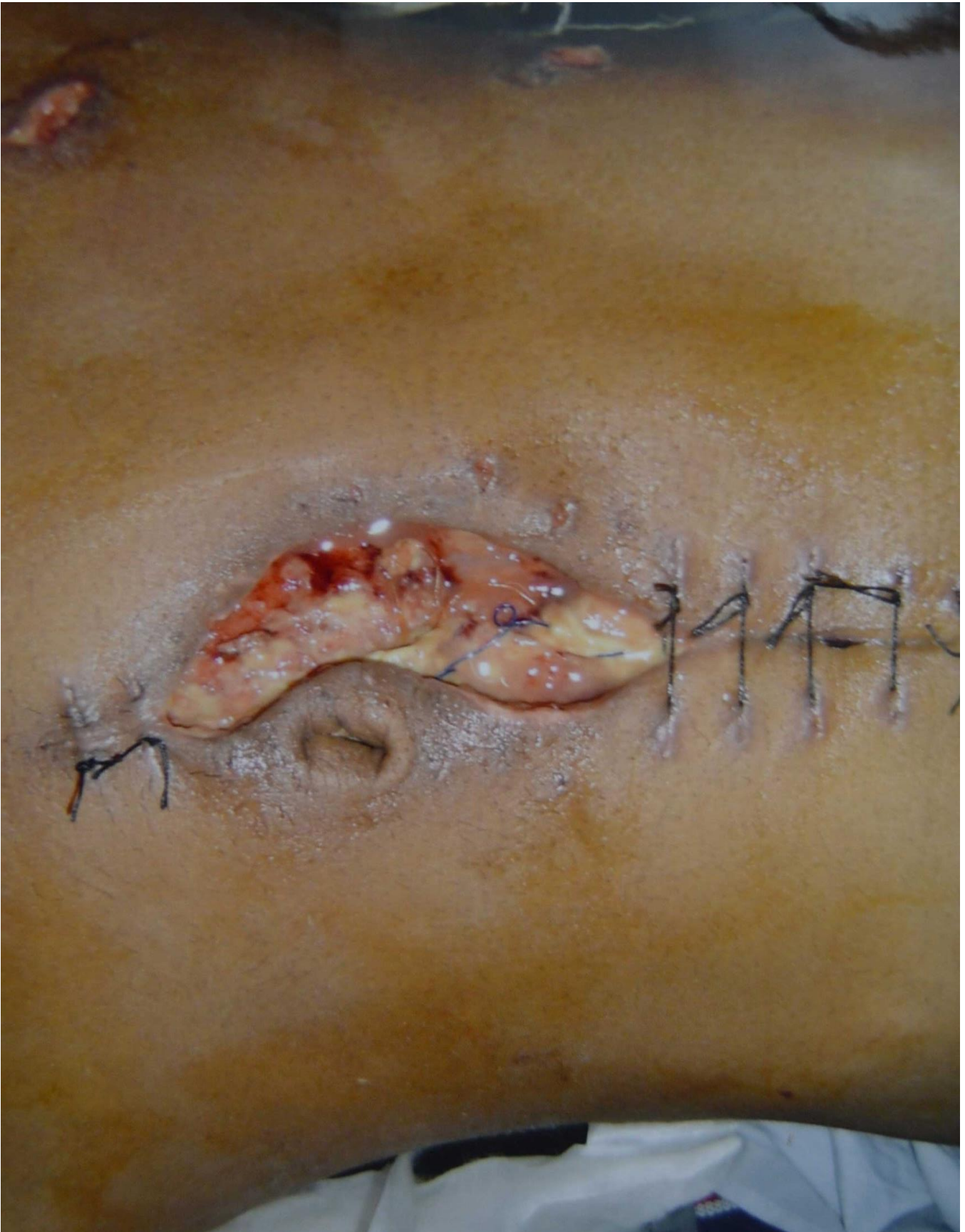Question 22 - PROP (Chest x-ray)



Question 25 - PROP (Clinical Photograph)



Question 26 - PROP (Clinical Photograph)



Question 27 - PROP (ECG)

